

## Myiasis of the External and Middle Ear

Kyle Hatten, MD; Yusuf Gulleth, MD; Tanya Meyer, MD; David J. Eisenman, MD

Aural myiasis is a rare otolaryngological disease typically seen in poor hygienic conditions and medically disabled patients. We present a case of aural myiasis in a healthy woman who had no apparent risk factors for infestation and required extensive surgical intervention. We also discuss the literature of documented otolaryngological cases of myiasis and effective therapies. In our patient, symptoms of otalgia, otorrhea, and tinnitus resolved after multiple attempts at extraction resulted in successful eradication of larvae. The patient required tympanoplasty to reconstruct the damaged external and middle ear. Physicians should have a clinical suspicion of aural myiasis in patients with a travel history and an atypical presentation of acute otalgia and otorrhea.

**Key Words:** myiasis, otalgia, otorrhea, tinnitus, tympanoplasty.

### INTRODUCTION

Myiasis is the infestation of human tissue by fly larvae that feed on the host's dead or living tissue and cause disease.<sup>1</sup> Larval survival in humans requires a specific combination of environmental and clinical conditions. Such conditions have been useful for larval debridement therapy of necrotic tissue.<sup>2</sup> However, unintentional infestation may manifest in otorhinolaryngological cavities that are conducive to larval growth, including the external auditory canal and nasal cavities.<sup>3</sup> Flies are generally attracted to the odor of decaying necrotic tissue, which can arise from chronic otorrhea or sinusitis. Certain populations are particularly susceptible to infestation, including children younger than 10 years of age and adults with mental or physical disabilities.<sup>4,5</sup> Because myiasis requires a rare combination of environmental, social, and medical risk factors, it is not surprising that there is limited literature describing it in humans.

Aural myiasis involves infestation of the external ear and/or middle ear. Two of the more common organisms associated with aural myiasis are the blowflies (Calliphoridae) and the flesh flies (Sarcophagidae).<sup>5,6</sup> Both have an attraction to decomposing matter, but they are also capable of consuming living tissue. Aural myiasis is a particularly rare condition in temperate climates such as the United States and typically presents in patients who live in poor hygienic conditions or in warm, humid climates. Chronic otorrhea has been implicated as a risk factor for aural myiasis in healthy, mobile patients.<sup>7</sup>

The clinical presentation of aural infestation is variable. Signs and symptoms include otalgia, otorrhea, perforation of the tympanic membrane, bleeding, tinnitus, vertigo, and impaired hearing.<sup>2-6</sup> Although most patients have an uncomplicated treatment course with aural myiasis, early intervention is key to avoiding complications involving adjacent structures.<sup>5</sup>

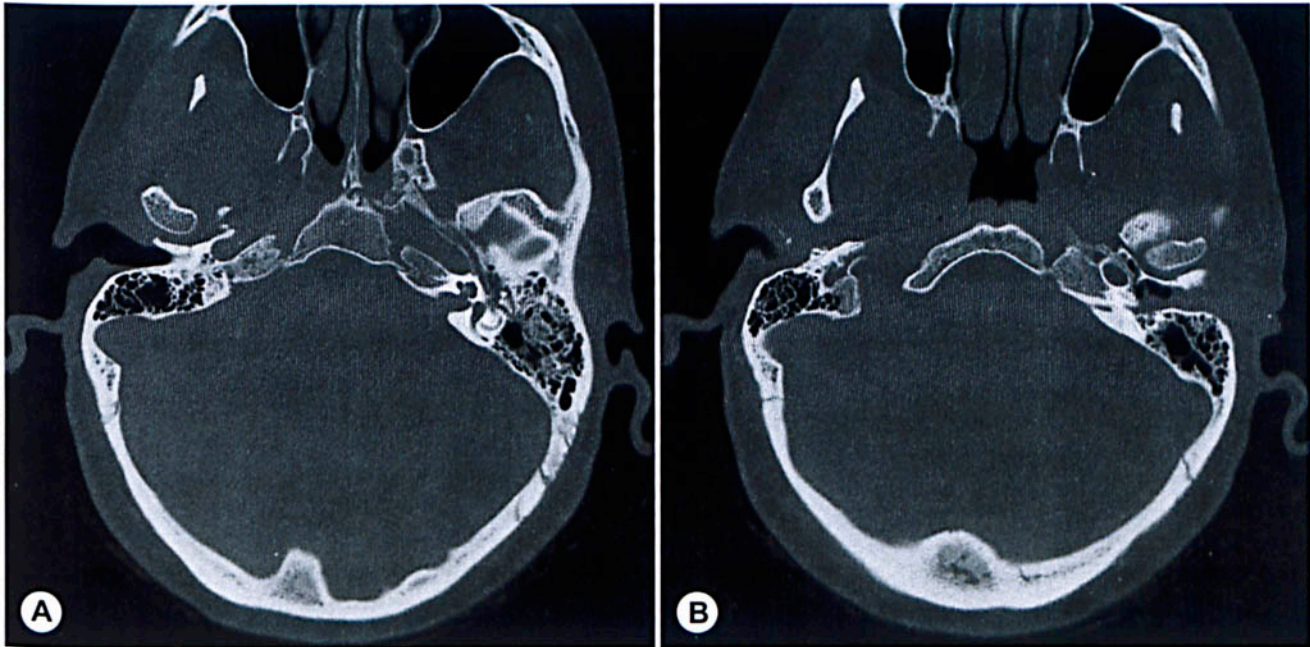
### CASE REPORT

A 44-year-old woman presented with 6 days of progressive left-sided otalgia, aural fullness, and tinnitus. She described the tinnitus as a perception of crackling in the ear accompanied by a somatic sensation of movement. The symptoms began shortly after she disembarked from an airplane on vacation in the Dominican Republic. She felt something fly into her left ear. A bug was removed by the treating physician, but 24 to 48 hours later she began to hear the tinnitus and felt pressure in the ear. She returned to the United States and sought consultation in our office. There was no history of chronic otitis or otologic trauma.

On examination, there was diffuse inflammation of the skin of the external auditory canal (EAC). Live insect larvae were seen filling the EAC, burrowing under the skin and extending through a posterior tympanic membrane perforation into the middle ear. Attempts at removing the larvae in the office were limited by discomfort and the extent of infestation in the middle ear. A computed tomography scan (Fig 1) demonstrated soft tissue thicken-

From the Department of Otorhinolaryngology–Head and Neck Surgery, University of Maryland School of Medicine, Baltimore, Maryland.

**Correspondence:** David J. Eisenman, MD, Dept of Otorhinolaryngology–Head and Neck Surgery, 16 S Eutaw St, Suite 500, Baltimore, MD 21201.



**Fig 1.** Computed tomography. **A)** Near-confluent opacification of right epitympanum, with intact ossicles. **B)** Opacification of right posterior mesotympanum and soft tissue density in external auditory canal.

ing of the skin of the EAC with soft tissue density in the EAC, mesotympanum, hypotympanum, and epitympanum.

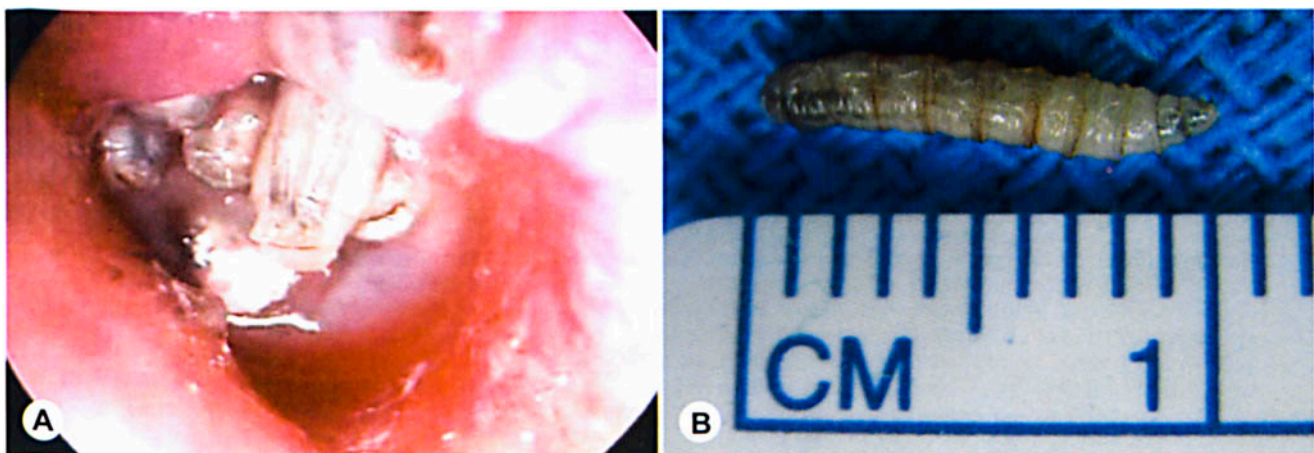
The patient was brought to the operating room for debridement under anesthesia. After debridement of the more superficial larvae, further larvae from deeper in the middle ear and under the skin of the EAC tended to migrate more superficially (Fig 2). This process was facilitated by instillation of sterile normal saline solution into the middle ear and removal of ambient light sources by temporary obstruction of the external auditory meatus. Endoscopic inspection of the middle ear was performed after completion of the procedure, and no further larvae were identified. On the first and second postoperative days, the

patient had a recurrence of the tinnitus and fullness. Otoscopic inspection revealed more larvae, which were debrided at the bedside. In total, approximately 30 larvae were removed from the ear.

On late follow-up, the patient was seen to have a subtotal tympanic membrane perforation, extensive middle ear fibrosis, and adhesions surrounding the ossicles and in the eustachian tube. She underwent successful underlay fascia tympanoplasty, and at 6-month follow-up had a slight residual conductive hearing loss and mild symptoms consistent with a patulous eustachian tube.

#### DISCUSSION

Historically, aural myiasis has presented in pa-



**Fig 2.** **A)** Endoscopic view of right external auditory canal, with maggots burrowing under skin and through tympanic membrane. **B)** View of single maggot after extraction.

tients with poor personal hygiene in tropical environments. The case presented in this report is unique in that it occurred in a healthy 44-year-old woman with no hygienic or socioeconomic risk factors conducive to egg deposition or larval growth.<sup>5</sup> In addition, she had a rare treatment course that was complicated in comparison to cases previously reported in the literature.

Traditionally, aural myiasis has been treated with manual extraction under binocular operative microscopy; however, this patient had tympanic membrane perforation and middle ear involvement that required multiple procedures under general anesthesia for complete extraction of the larvae.<sup>6</sup> After initial removal of the more accessible larvae, the deeper larvae tended to migrate superficially, facilitating their debridement. Our patient also had extensive mesotympanic infestation with middle ear fibrosis and required subsequent tympanoplasty for repair of a large perforation. Successful tympanoplasty has not been previously documented in the course of treatment for aural myiasis.<sup>5</sup>

In distinction to previously reported cases, our

patient's symptoms persisted after initial extractions of the larvae from the auditory canal and middle ear. She required several debridements in the operating room and at bedside. Prior case reports have described complete resolution of symptoms after the initial removal of the larvae. Thus, any recurrence of symptoms in the immediate postdebridement period suggests persistent infestation that needs to be addressed.<sup>8,9</sup>

In summary, clinicians must have a clinical suspicion of aural myiasis in patients with a travel history and an atypical presentation of acute otalgia and otorrhea. Additionally, the treatment of individuals with the disease should yield complete postoperative resolution of symptoms; otherwise, persistent infestation is likely. It is crucial to have immediate and complete debridement of the infestation to prevent further complications. Persistent tympanic membrane perforation due to aural myiasis can be successfully repaired with surgical tympanoplasty. Extensive middle ear fibrosis may be present, which can complicate surgical repair, and could place the patient at risk for long-term eustachian tube dysfunction.

#### REFERENCES

1. Beaver PC. Clinical parasitology. 9th ed. Philadelphia, Pa: Lea & Febiger, 1984.
2. Whitaker IS, Twine C, Whitaker MJ, Welck M, Brown CS, Shandall A. Larval therapy from antiquity to present day: mechanisms of action, clinical applications and future potential. *Postgrad Med J* 2007;83:409-13.
3. Sood VP, Kakar PK, Wattal BL. Myiasis in otorhinolaryngology with entomological aspects. *J Laryngol Otol* 1976;90:393-9.
4. Yuca K, Caksen H, Sakin YF, et al. Aural myiasis in children and literature review. *Tohoku J Exp Med* 2005;2006:125-30.
5. Werminghaus P, Hoffmann TK, Mehlhorn H, Bas M. Aural myiasis in a patient with Alzheimer's disease. *Eur Arch Otorhinolaryngol* 2008;265:851-3.
6. Keller AP Jr, Keller AP III. Myiasis of the middle ear. *Laryngoscope* 1970;80:646-50.
7. Maturo S, Michaelson MD, Horlbeck D, Brennan J. Auricular myiasis. *Otolaryngol Head Neck Surg* 2007;136:668-9.
8. Baker MC. Green-bottle fly worm infestation of the ear. Myiasis of the ear caused by *Phaenicia sericata*. *Laryngoscope* 1953;63:545-8.
9. Magliulo G, Gagliardi M, D'Amico R. Human aural myiasis. *Otolaryngol Head Neck Surg* 2000;122:777.