

Human and Other Mammalian Bite Injuries of the Hand: Evaluation and Management

Stephen A. Kennedy, MD

Laura E. Stoll, MD

Alexander S. Lauder, MD

Abstract

The hand is the most common site for bite injuries. Because of specific characteristics of hand anatomy, bite mechanics, and organisms found in human and animal saliva, even small wounds can lead to aggressive infections. Failure to recognize and treat hand bites can result in significant morbidity. Human and animal bites most commonly lead to polymicrobial bacterial infections with a mixture of aerobic and anaerobic organisms. *Pasteurella* species are commonly found in dog and cat bite wounds, and *Eikenella* is characteristic of human wounds. *Staphylococcus*, *Streptococcus*, and anaerobic bacterial species are common to all mammals. Although public health measures in developed countries have been highly effective at reducing rabies transmission, dog bites remain the most common source of rabies infection worldwide. Human bites can transmit HIV, hepatitis B, or hepatitis C, especially when contaminated blood is exposed to an open wound. Appropriate management of any mammal bite requires recognition, early wound cleansing, evaluation of injured structures, and infection prophylaxis. Structural repair is performed as indicated by the severity and contamination of the injury, and wounds may require delayed closure. Wound infections typically require débridement, empiric antibiotics, and delayed repair or reconstruction.

From the Department of Orthopaedics and Sports Medicine, University of Washington, Seattle, WA.

None of the following authors or any immediate family member has received anything of value from or has stock or stock options held in a commercial company or institution related directly or indirectly to the subject of this article: Dr. Kennedy, Dr. Stoll, and Dr. Lauder.

J Am Acad Orthop Surg 2015;23:47-57

<http://dx.doi.org/10.5435/JAAOS-23-01-47>

Copyright 2014 by the American Academy of Orthopaedic Surgeons.

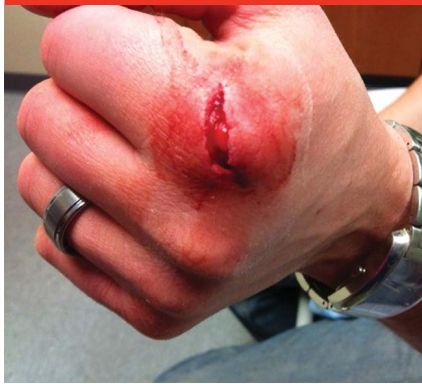Human and animal bites are common hand injuries.^{1,2} Most bites are from dogs, cats, and humans.^{2,3} These injuries prompt as many as 330,000 emergency department visits in the United States annually.⁴ However, the true incidence is difficult to ascertain because minor injuries are often self-treated without the advice of a healthcare provider.⁵ Population studies suggest that, in the United States, approximately 4.5 million people (1.5% of the population) are bitten annually by dogs alone.³ The estimated healthcare cost associated with management of cat and dog bites in the United States is >\$850 million annually and does not take into

account the costs to the patient in terms of time off work, rehabilitation, and permanent impairment.⁶

Epidemiology

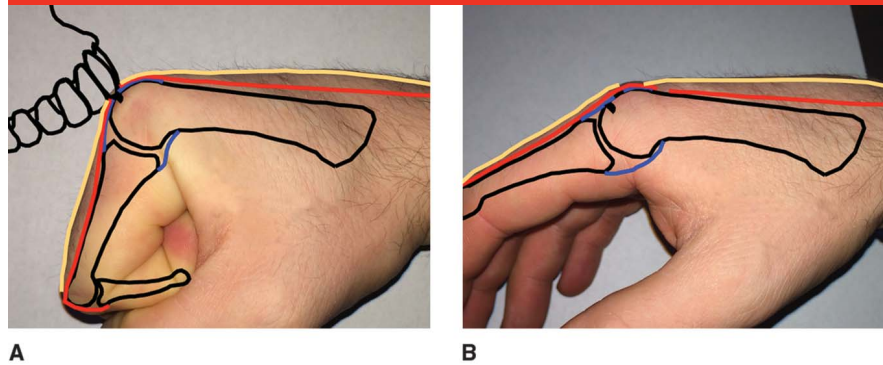
In a lifetime, approximately >50% of the population will sustain an animal bite.¹ Of these bites, >90% are from domestic animals, and most will occur during childhood.^{1,6} Dogs are responsible for 80% to 90% of bites.⁷ Whether specific breeds are more dangerous than others is a subject of controversy.^{5,8-11} The American Veterinary Medical Association and US Centers for Disease Control and Prevention have argued

Figure 1



Clinical photograph of the hand demonstrating an acute fight bite at the metacarpophalangeal joint of the first finger. (Copyright Ohio State University Department of Emergency Medicine, Columbus, OH.)

Figure 2



A, Illustration demonstrating the typical position of the hand at the time of impact against the teeth, which results in a fight bite or reverse bite injury. **B**, Illustration demonstrating the position of the disrupted skin (yellow line), tendon (red line), and joint capsule (blue line) when the hand returns to a relaxed position. Note that the tendon disruption is not immediately visible within the skin wound, and the capsular tear is covered with tendon, creating a closed space that can lead to infection.

against breed-specific legislation and advocate instead for community measures for bite prevention.^{9,10} In most cases, the patient is familiar with the animal responsible for the bite injury.^{3,11} Cat bites are the second most common domestic animal bite, constituting 5% to 15% of all bites.^{2,7,8} Dog bites are more common in boys and men, and cat bites are most common in adult women.^{2,7}

Human bites are less common than domestic animal bites, accounting for 2% to 3% of hand bites.¹² These bites can be categorized as (1) clenched fist injuries (“fight bites”), which result from the impact of the hand against the teeth during a fight, or (2) occlusive bite injuries, which are caused by the teeth closing directly on tissue. Patients with clenched fist injuries are typically male, the dominant hand is usually involved, and the bite most often occurs at the metacarpophalangeal (MCP) joints of the hand.¹³ Occlusive bites occur more often in women than in men and are more frequently inflicted by men.¹⁴ Occlusive bites to the breasts, arms, genitals, or legs are most often seen in women,

whereas bites to the shoulders, arms, and hands are most often seen in men.¹⁴ Human bites can result from altercations, assault, abuse, sexual activities, or self-defense. The true incidence of human bites is likely underestimated because patients may not seek medical attention.

Anatomy and Mechanism of Injury

Anatomy

Because of the unique anatomy of the hand, bite wounds may appear small. However, tendons, bones, nerves, blood vessels, and joint structures are superficial and at risk of injury. The skin of the hand is generally well perfused, but inoculation with polymicrobial oral flora leads to infectious spread along structures with relatively low vascularity such as tendons, ligaments, bones, and cartilage. Following a bite injury, cellulitis, abscess, infectious tenosynovitis, septic arthritis, osteomyelitis, and even sepsis can develop, predisposing the hand to long-term morbidity.¹⁵

Clenched Fist Injuries

Clenched fist injuries, which are also known as fight bites or reverse bite injuries, are the most common form of human hand bites (Figure 1). These injuries result from the impact of a clenched fist against the teeth of another person. The MCP joint is most frequently involved because of its prominence when a fist is clenched. The overlying skin is taut at the time of impact, leaving little soft-tissue protection. In a study of 191 patients with clenched fist injuries, the authors found that the teeth often penetrated the extensor mechanism and joint capsule (67%), leading to injury of the articular cartilage and bone.¹³ When the hand subsequently returns to a relaxed position, retraction of the extensor tendon removes the injured tendon from view in the skin wound and seals the capsular tear, creating a closed environment ideal for bacterial growth and the development of septic arthritis¹⁶ (Figure 2). Infection may also spread to the subcutaneous space, subaponeurotic space, and along the lumbrical muscle, leading to infection in the palm and flexor tendon sheaths.

Occlusive Human Bites

Occlusive bite wounds are caused by direct closure of the teeth on tissue. If the fingers are involved, bites often penetrate the dorsal and volar skin to inoculate the tendon or joint capsule with oral flora. Severe bites may result in traumatic amputation of the finger through the distal phalanx or distal interphalangeal joint. In more proximal bites, a semicircular imprint of the teeth is often seen at the location of the bite, with variable depth of penetration and injury to the underlying structures. Infections are less common in proximal occlusive bites than in bites to the hand and wrist.⁶

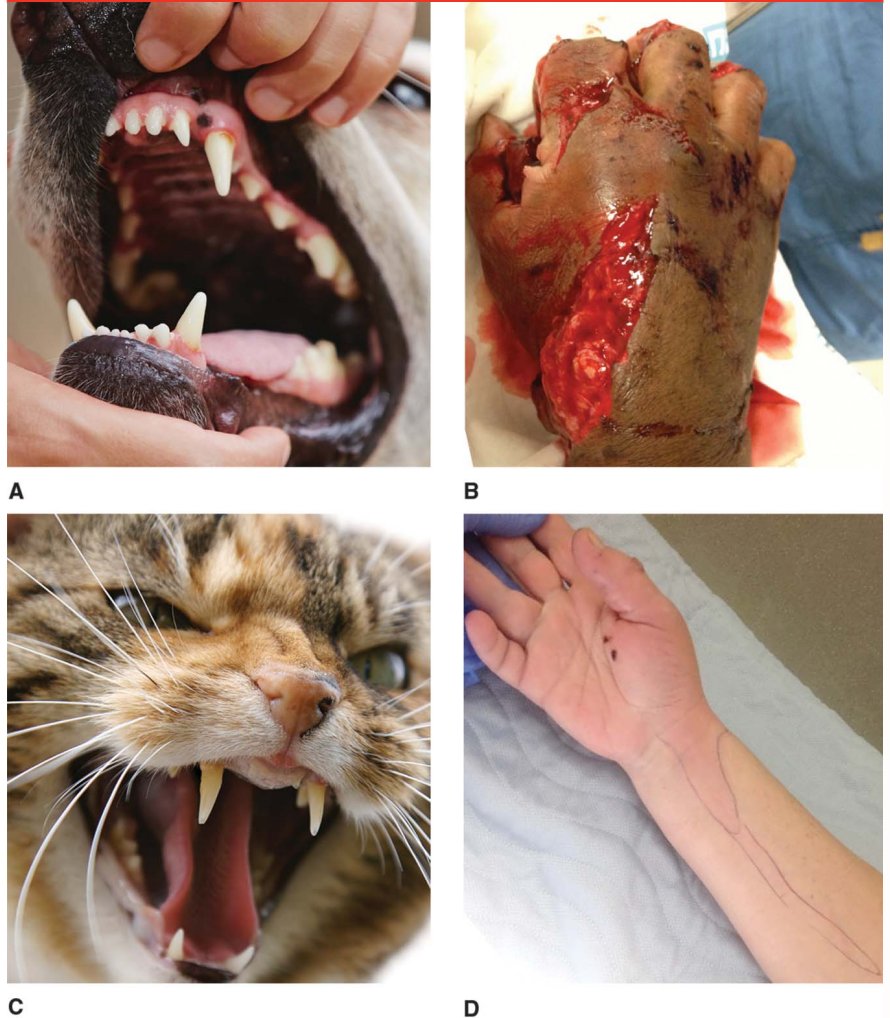Dog Bites

The severity of a dog bite is correlated with dog size, breed, training, and circumstances of the bite.^{3,9-11} Large breeds, particularly those trained as attack, guard, and police dogs, tend to inflict more damage. Adult canine jaws are capable of exerting bite forces of >300 lbs.¹⁷ The teeth vary in shape from long sharp canine teeth to more rounded incisors, premolars, and molars with grinding surfaces (Figure 3, A). This variety of shapes has evolved to clamp and hold, tear, and crush food. Crush wounds, devascularization, and soft-tissue avulsion result from high pressures and shearing (Figure 3, B). The injury is further compromised by direct inoculation with oral flora. In severe bites, soft-tissue coverage may be required following wound débridement.

Cat Bites

Although cats do not have the jaw strength of dogs, they do have sharp, narrow teeth that have evolved to pierce and tear the tissue of small prey (Figure 3, C). This dental anatomy causes puncture-type wounds,

Figure 3



A, Photograph demonstrating typical dog dental anatomy. (Copyright iStock.com/chalabala) **B**, Clinical photograph of the hand demonstrating soft-tissue tearing and avulsion injuries resulting from a dog bite. **C**, Photograph demonstrating typical cat dental anatomy. (Copyright iStock.com/rblake80) **D**, Clinical photograph of the hand and forearm demonstrating ascending lymphangitis following a cat bite to the hand. (Copyright Amanda Roof, MD, Seattle, WA.)

piercing deeply to enter the joint capsule or inoculate the periosteum and bone with oral flora (Figure 3, D). An estimated 30% to 50% of cat bites are complicated by infection, whereas infections associated with dog bites typically occur at less than half that rate.⁷ Cat bites result in a higher rate of infectious sequelae and invasive treatment among patients who present for medical treatment.⁸

Disease Transmission and Bacteriology

Human Bites

Human bites have a reputation for causing severe hand infections. In human saliva, >600 bacterial species have been identified.¹⁸ Cultures of bite wounds are frequently polymicrobial, typically with four isolates per culture.^{19,20} The common

Table 1

Bacteria Typically Isolated From Infected Bite Wounds ¹⁹⁻²¹		
Source	Aerobic Bacteria	Anaerobic Bacteria
Human	<i>Streptococcus</i> species, <i>Staphylococcus</i> species, <i>Eikenella corrodens</i> , <i>Haemophilus</i> species, <i>Enterobacteriaceae</i> , <i>Gemella morbillorum</i> , <i>Neisseria</i> species, other organisms	<i>Prevotella</i> species, <i>Fusobacterium</i> species, <i>Eubacterium</i> species, <i>Veillonella</i> species, <i>Peptostreptococcus</i> species, other organisms
Dog	<i>Pasteurella</i> species, <i>Streptococcus</i> species, <i>Staphylococcus</i> species, <i>Neisseria</i> species, <i>Corynebacterium</i> species, <i>Moraxella</i> species, <i>Enterococcus</i> species, other organisms	<i>Fusobacterium</i> species, <i>Porphyromonas</i> species, <i>Prevotella</i> species, <i>Propionibacterium</i> species, <i>Bacteroides</i> species, <i>Peptostreptococcus</i> species, other organisms
Cat	<i>Pasteurella</i> species, <i>Streptococcus</i> species, <i>Staphylococcus</i> species, <i>Neisseria</i> species, <i>Corynebacterium</i> species, <i>Moraxella</i> species, <i>Enterococcus</i> species, other organisms	<i>Fusobacterium</i> species, <i>Porphyromonas</i> species, <i>Prevotella</i> species, <i>Propionibacterium</i> species, <i>Bacteroides</i> species, other organisms

Table 2

Viral Infections Transmitted by Human and Animal Bites	
Bite Source	Viruses
Human	HIV, hepatitis B, hepatitis C, herpes simplex
Dogs, ^a bats, raccoons, skunks, and other rodents	Rhabdoviridae (rabies)
Rats and mice	Hantavirus
Monkeys (especially macaques)	Simian B

^a In areas where rabies is endemic

aerobic and anaerobic bacteria isolated from human bite infections are listed in Table 1.^{19,21} *Eikenella corrodens* was isolated in 17% to 30% of cases in several studies.¹⁹⁻²¹ The high level of infectivity associated with human bites may be attributed to the combination of virulence factors from multiple bacteria. Pure gram-negative or anaerobic infections are uncommon.^{19,20}

HIV, hepatitis B (HBV), and hepatitis C (HCV) can be transmitted by human bites, but this rarely occurs²² (Table 2). Salivary inhibitors usually inactivate the infectious potential of the HIV virus, making the risk of transmission from saliva alone essentially negligible.^{22,23} Risk is significantly increased when blood is present, however (0.1% to 0.3%).²² If HIV infection is known or suspected and there was visible blood present at

the time of injury, the CDC recommends postexposure prophylaxis with highly active antiretroviral therapy.²² This is a combination of antiretroviral medications used to treat AIDS; a 28-day prophylactic course is recommended after exposure.²² The patient should also have a baseline blood test to determine preexposure HIV status, with retesting performed at 3 and 6 months.²²

HBV can be transmitted via saliva only if the skin is pierced. The use of postexposure prophylaxis is considered if the exposure results in bleeding.^{22,23} An HBV surface antigen titer should be obtained regardless of vaccination status.^{22,23} If the HBV status of the biter is unknown, and HBV antibodies are insufficient or absent, then the accelerated course of the HBV vaccine may be administered.^{22,23} Postexposure follow-up

for HCV does not include medication but does include a baseline anti-HCV test with retesting performed at 4 and 6 months.^{22,23} When a bite occurs during an altercation, testing of both parties is recommended because blood-borne illness can be transmitted from the patient to the biter.^{22,23}

Dog and Cat Bites

Like infections associated with human bites, most infections resulting from dog and cat bites are polymicrobial, regardless of wound type or clinical presentation.²¹ In a study of 107 patients with infections caused by dog or cat bites, mixed aerobes and anaerobes constituted >50% of wound cultures, with an average number of five bacterial isolates per sample.²⁴ Aerobic and anaerobic bacterial species commonly isolated from dog and cat bites are listed in Table 1. In several studies, *Pasteurella* species were the most frequently found isolates in cultures of dog (50%) and cat (75%) bites.^{7,24,25}

Pasteurella is a gram-negative, facultative, anaerobic, pleomorphic coccobacillus that causes an early and severe inflammatory response.²⁴ *P canis* is most commonly found in dogs, whereas *P multocida* and *P septica* are most commonly found in

cats.²⁴ The laboratory should be informed of the bite type and the potential for *Pasteurella* isolates.^{7,24,26} Cultures require appropriate growth media and may take up to 1 week to grow.

Capnocytophaga canimorsus infection after a dog bite is rare but deserves mention because it can lead to cellulitis, sepsis, meningitis, endocarditis, disseminated intravascular coagulation, acute respiratory distress syndrome, organ damage, and death.¹⁵ Virulence is low in healthy persons, but this infection can result in significant morbidity in elderly or immunocompromised patients. In the setting of sepsis, reported rates of mortality ranging from 30% to 60% have been reported.¹⁵ After an incubation period of up to 1 week, clinical manifestations include fever, chills, myalgia, vomiting, malaise, petechial rash, and purpuric lesions. Management includes hospital admission and immediate antimicrobial therapy.¹⁵

Bites From Other Mammals

Other mammalian species such as bats, raccoons, skunks, rats, and other nondomestic animals are infrequent sources of hand bites. Bites from these animals have the potential to transmit rabies as well as uncommonly encountered diseases such as rat-bite fever, hantavirus, and other illnesses.²⁷ Whenever possible, the animal involved should be captured and tested. Urgent infectious disease consultation is recommended for unusual bites. For example, bites from laboratory macaque monkeys may transmit simian B virus, which is fatal in 80% of untreated humans.²⁸

Rabies

Dog bites are the most common source of rabies worldwide.^{29,30} More than 55,000 deaths are attributed to rabies annually. Most of these fatalities occur in developing

countries with a high population of stray dogs. In countries where rabies is endemic, patients who are bitten should be treated based on the assumption that the dog was infected.

In the United States, rabies infection is rare and is most commonly transmitted by bats.³⁰ Bats, raccoons, skunks, and foxes are the most common carriers of rabies in the United States.³⁰ In patients with a bite from one of these animals, the clinician must maintain a high index of suspicion for rabies exposure because of the severity of the illness and the need to institute prophylaxis. The animal should be captured and tested. Postexposure prophylaxis is initiated until the disease can be ruled out in the offending animal.²⁹

Tetanus

Clostridium tetani is not commonly found in wounds associated with human, dog, or cat bites, but *Clostridium* spores are ubiquitous, and tetanus is potentially fatal.³¹ In patients who have been bitten, administration of tetanus toxoid is recommended for those who have not received a booster within 5 years, and immunoglobulin should be administered to those who have had two or fewer previous tetanus immunizations.³¹

Diagnosis and Evaluation

History

Symptoms of infection can occur within 12 hours of injury.^{24,25} Infections related to cat bites develop as early as 3 hours after the incident in approximately 50% of cases. The most prominent symptoms include erythema, edema, progressive pain, and fever.

Obtaining a pertinent medical history is essential to evaluate the patient for an increased risk of infection. The

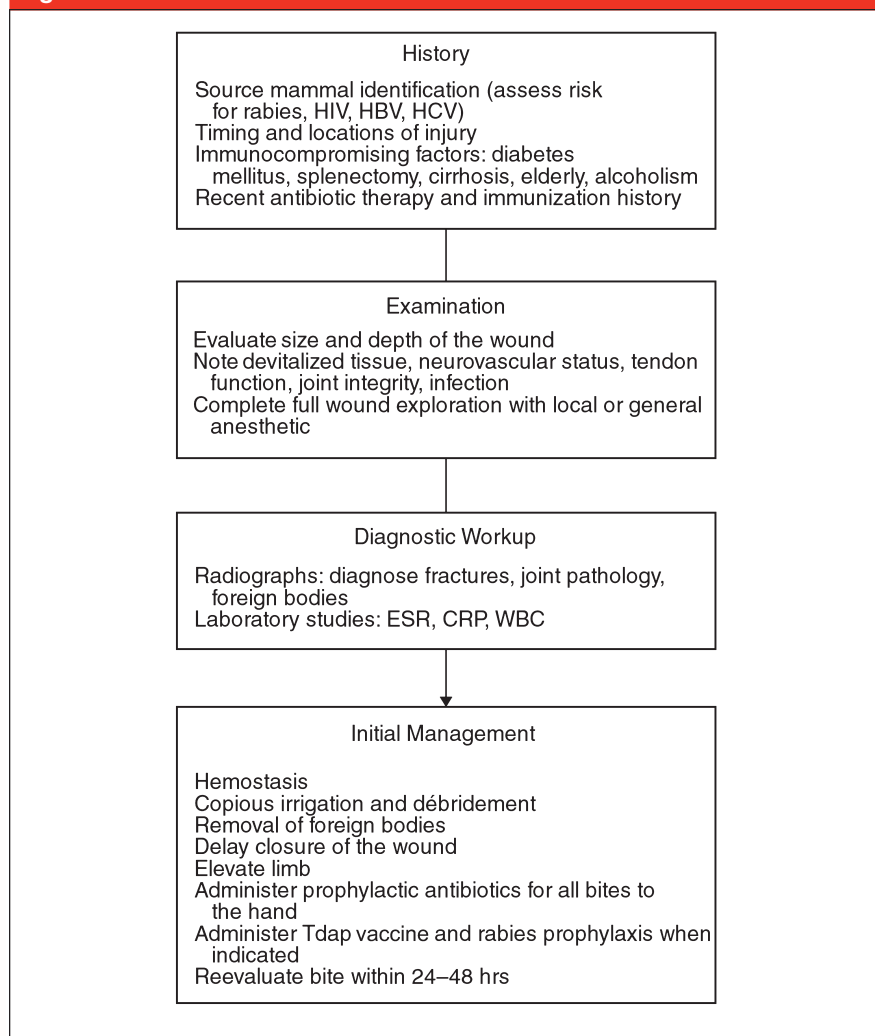
timing and location of injury, patient factors (eg, immunocompromised status, age), immunization history, and recent history of antibiotic therapy should be considered when determining treatment (Figure 4). In patients with prosthetic joints, there is a risk of blood-borne seeding if bacteremia develops. In cases of clenched fist injuries, it may be difficult to obtain an adequate history because of the patient's reluctance to disclose the circumstances surrounding the injury, but this is essential in counseling the patient regarding transmission of blood borne illnesses.

Physical Examination

The size and depth of the wound and the amount of devitalized tissue should be assessed along with potential damage to neurovascular structures and tendons, underlying fractures, the presence of exposed bone, the integrity of the joint, and the presence of infection. A bite wound located over a joint or tendon is a risk factor for more severe infection, which could require hospitalization.³² Fight bites may be overlooked by the patient and healthcare provider because of the small lacerations that characterize these injuries. In addition, the patient may be intoxicated and/or the healthcare provider may be focused on the potential for other fractures, lacerations, and injuries.

During the examination, particular attention should be paid to the function of the extensor mechanism. The intrinsic muscle attachments to the lateral bands can allow proximal interphalangeal (PIP) joint extension despite complete disruption of the central slip over the PIP joint or the extensor tendon more proximally.³³ Extension at the MCP joint should be evaluated, and the Elson test should be performed to evaluate for disruption of the extensor

Figure 4



Algorithm for initial evaluation and management of an acute hand bite. CRP = C-reactive protein, ESR = erythrocyte sedimentation rate, HBV = hepatitis B virus, HCV = hepatitis C virus, Tdap = tetanus, diphtheria, and pertussis, WBC = white blood cell count

mechanism.³³ During the Elson test, resisted PIP joint extension is assessed with the PIP joint flexed to 90° over the edge of a table. If PIP joint extension is weak and the distal interphalangeal joint hyperextends, rupture of the central slip is likely. Sagittal band rupture should be evaluated by performing an extensor lag examination at the MCP joint. Sagittal band disruption may allow extensor tendon subluxation between the metacarpal heads, preventing active extension of the MCP joint,

whereas passive extension centralizes the tendon and allows for maintenance of an extended position.

In children with human occlusion bites, the intercanine distance can be used to evaluate whether a child or an abusive adult inflicted the bite.³⁴ Adults have an intercanine distance of 3.0 to 4.5 cm, whereas the distance is 2.5 to 3.0 cm in children.³⁴ This method lacks some specificity because adult dentition is present by age 12 years; therefore, the bite should be photo-

graphed to document possible assault or abuse.

Diagnostic Imaging

Plain radiographs are used to evaluate for underlying fractures, joint pathology, and foreign bodies. Although often unremarkable, radiography may demonstrate fracture, impaction injuries of bone, tooth fragments, or air in the joint or soft tissues. Radiography is also useful for detecting osteomyelitis. A puncture wound with associated fracture is at high risk for osteomyelitis. In patients with advanced infection, radiographic findings that indicate osteomyelitis include periarticular osteoporosis, joint space narrowing, bony erosion, and periostitis. Ultrasonography can demonstrate fluid collection and vascular injury.⁷

Laboratory Tests

Although laboratory studies are not routinely ordered after an acute hand bite, they may be useful for detecting possible infection. Erythrocyte sedimentation rate, C-reactive protein level, and white-blood cell count can help to evaluate the patient for systemic inflammation and can be used as a baseline for treatment. However, these studies may be normal even in the presence of infection, or the results may be elevated in patients with other sources of inflammation or infection; therefore, these studies should not be used alone to diagnose or rule out infection.^{7,35,36}

In patients with infection, cultures should be obtained (preferably from intraoperative wound tissue samples) to detect aerobic and anaerobic bacteria. The bite source and potential presence of organisms should be communicated to the laboratory because *Eikenella*, *Pasteurella*, and other organisms may be difficult to isolate.^{24,26} In patients with acute bites without infection, swabs for culture are unreliable and are typically not recommended.

Management

Prophylaxis

Although routine antibiotic prophylaxis is not necessarily recommended for all bite wounds, it is recommended for hand bites.⁶ In a review of eight randomized controlled trials, Medeiros and Saconato⁶ showed that hand and wrist bites are an independent risk factor for infection, and antibiotic prophylaxis reduces infection from 28% to 2% (number needed to treat = 4). Even in patients who present early (<24 hours) and are free of infection, tendon injury, or joint injury, bedside débridement and wound care alone are insufficient.⁶ High-risk populations and patients with puncture wounds, crush injuries with devitalized tissue, or deep wounds that cannot be cleansed easily particularly benefit from antibiotic prophylaxis.

Broad antibiotic coverage is recommended to address the polymicrobial nature of common oral flora and bite infections. For example, *E. corrodens* and *Pasteurella* species are generally susceptible to penicillin and ampicillin,²⁶ but staphylococci and anaerobic species often produce β -lactamase, which provides resistance to these antibiotics.²² The addition of a β -lactamase inhibitor significantly increases the effectiveness of these antibiotics, and amoxicillin-clavulanate is the oral antibiotic of choice for human, dog, and cat bites.^{26,37,38} Oral and intravenous antibiotic options and alternative medications are listed in Table 3. Cephalexin, dicloxacillin, and erythromycin should not be used because they demonstrate poor activity against *Eikenella* and *Pasteurella*.

In cases in which rabies transmission is possible, irrigation and débridement, the use of soap, and the application of alcohol or povidone-iodine to the wound can reduce the likelihood of transmission by

Table 3

Empiric Antibiotic Prophylaxis for Human, Dog, and Cat Bites^{a,36,37}

Route	Agents of Choice	Alternate Regimens
Oral	Amoxicillin-clavulanate	One of the following: ^b Doxycycline, trimethoprim-sulfamethoxazole, penicillin VK, cefuroxime, fluoroquinolones (ciprofloxacin or moxifloxacin)
Intravenous	Ampicillin-sulbactam, piperacillin-tazobactam, ticarcillin-clavulanate, ceftriaxone plus metronidazole	Fluoroquinolones (eg, ciprofloxacin) plus metronidazole, carbapenem monotherapy (eg, imipenem, meropenem, ertapenem)

^a Same for all three types of bites

^b Plus clindamycin or metronidazole

90%.²⁹ Rabies vaccine and immunoglobulin are given in high-risk situations. Immunoglobulin provides immediate virus-neutralizing antibodies while the vaccine induces host-immune production of antibodies within 7 to 10 days.²⁹ Multiple doses of rabies vaccination can be discontinued once testing of the source animal has excluded rabies.

Wound Management

Management of the wound partially depends on its size, character, and the presence or absence of infection. When multiple tiny punctures associated with a bite from a cat or small dog are treated with antibiotics, lancing of the punctures is not typically required unless infection develops. Open wounds, however, should be irrigated and débrided.

The goals of initial wound management include hemostasis, copious irrigation, removal of foreign bodies, and excisional débridement of devitalized tissue. The use of local anesthesia for evaluation of the wound provides the opportunity for a more thorough assessment, irrigation, and débridement. During wound exploration, the hand is assessed for tendon disruption, bone or joint penetration, open fracture, neuro-

vascular injury, and deep tissue infection.^{5,7}

In patients with acute clenched fist injuries (fight bites), the wound can be extended to provide adequate exposure for inspection. Arthrotomy and inspection of the joint surface may be beneficial even if the capsule appears to be intact because puncture wounds can quickly seal off. Part of the penetrating tooth is occasionally retained and should be removed at the time of exploration.¹³ Insufficient evidence exists to determine whether exploration in the operating room is necessary for all acute fight bites.³⁹ These injuries are often treated with irrigation and débridement in the emergency department and an intravenous dose of antibiotic. The patient is discharged with oral amoxicillin-clavulanic acid, and close follow-up is recommended.

The time from injury to treatment is important. Basadre and Parry⁴⁰ retrospectively reviewed 124 patients with human bite injuries to the hand. Forty-seven patients were seen within 24 hours of injury, 51 presented 1 to 7 days after injury, and 26 presented ≥ 7 days after injury.^{39,40} Of the patients who presented within 24 hours, 78% received wound care only and 22% underwent surgical débridement, but

all had excellent functional outcomes.^{39,40} Among the patients who presented between 1 and 7 days after injury, those without infection also had good outcomes independent of the initial treatment, but patients with infection lost motion and grip strength if surgical débridement was not performed.^{39,40} Complications included septic arthritis, osteomyelitis, and tenosynovitis. For patients who presented ≥ 7 days after injury, 93% were treated surgically and had good outcomes.^{39,40}

Surgical Repair

Tendon repair, tendon transfer, osteosynthesis, vascular repair, revision amputation, and/or soft-tissue coverage can be performed if the tissues are adequately débrided.⁵ Successful results have been achieved with primary flexor tendon and extensor tendon repairs after human bites.⁴¹ Whether exploration and surgical repair is performed in the emergency department or in the operating room depends on injury factors, patient factors, and local resources. However, patients with flexor tendon lacerations, bone penetration, and extensive devitalization or contamination will likely benefit from treatment in the operating room.

Suture closure of acute bite wounds on the hand is a controversial topic. Leaving these wounds open for bacterial egress has been recommended.⁴²⁻⁴⁵ However, recent studies of emergency management of these injuries show substantial improvement in cosmetic appearance with primary closure (particularly for facial wounds), with little or no increased risk of infection.⁴²⁻⁴⁴ In a study of 145 patients with bite wounds treated with primary closure, Chen et al⁴⁵ acknowledged that infection rates may have been slightly higher in their study population (6% versus 3.4% for the standard sutured wound infection rate

at the same institution in the same time frame); however, this rate may be an acceptable trade-off for improved cosmetic appearance. Other studies also included bites to all body regions and found no difference between patients who underwent suture closure and those who did not.^{43,44} However, these studies are underpowered to draw conclusions from on the effect of suture closure for hand bites in particular. Studies consistently confirm that bites to the hand are a subset of injuries that have a higher risk of infection than do bites to other areas of the body.^{42,43} Leaving a wound open is not a substitute for antibiotic therapy or irrigation and débridement. Heavy contamination or uncertain adequacy of débridement remains a contraindication to primary closure.

Postoperative management of bite wounds should include elevation, wound care, and antibiotics. Careful follow-up is required to monitor the progression of healing. The patient should be counseled to return immediately if symptoms worsen.

Infection

Following a diagnosis of infection, expeditious treatment is required to prevent progression. Tissue cultures are preferred over culture swabs because of the improved accuracy in diagnosing bacterial pathogens. Most infections are treated with irrigation, excisional débridement, and delayed closure. All necrotic tissue should be débrided (Figure 5). Infected bone should be excised and loose fragments of articular cartilage should be removed. In severe cases, significant bone excision is required, and patients should be advised early of the potential risk for later amputation.^{35,36} After débridement, leaving wounds open to heal by secondary intention facilitates bacterial egress. Patients with estab-

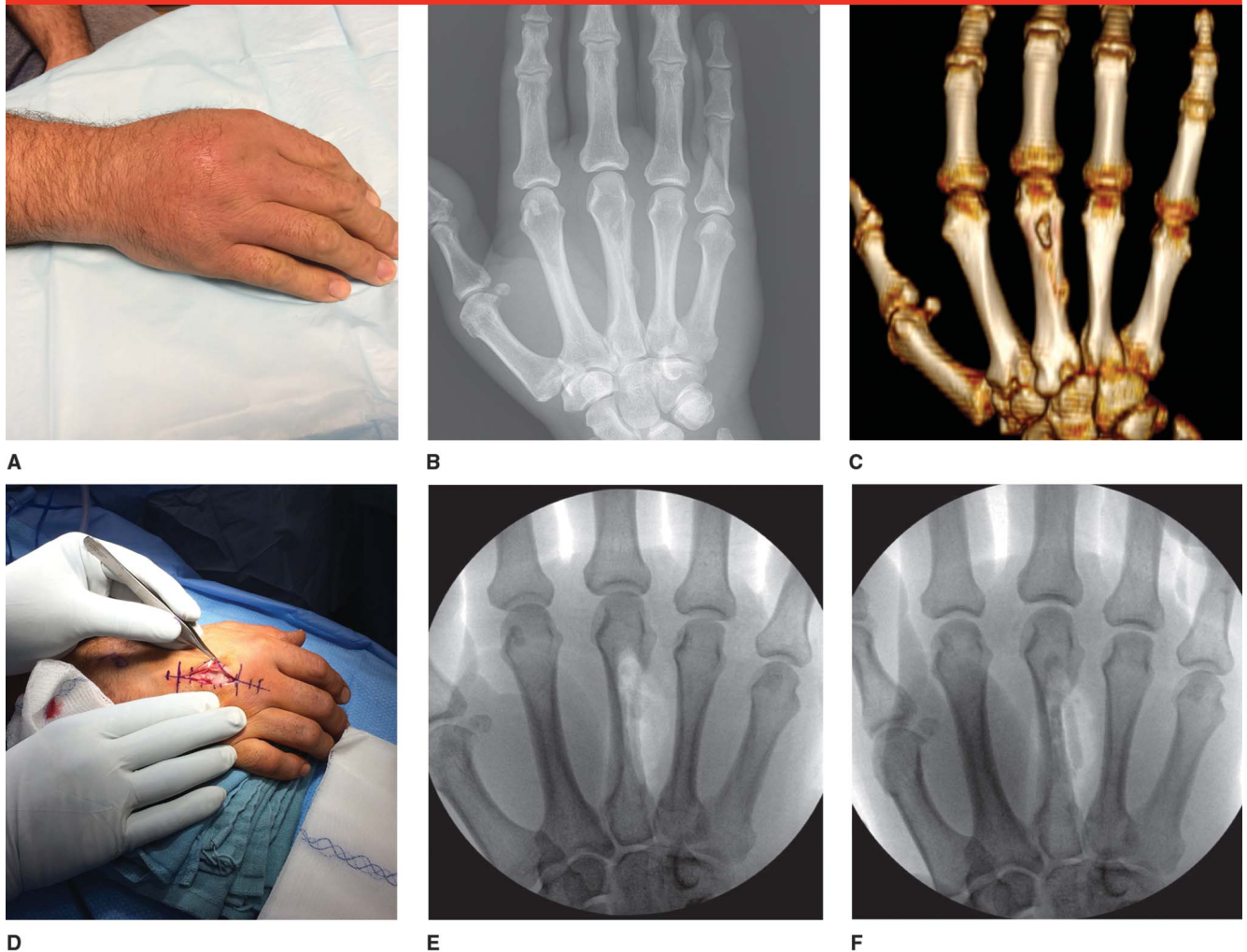
lished infection may benefit from hospitalization and repeat débridement as needed.

Scant data are available to guide the healthcare provider with regard to the appropriate duration of antibiotic treatment. In general, the duration of therapy is based on the severity of the infection. For example, antibiotic treatment for cellulitis is typically 10 to 14 days, whereas treatment for tenosynovitis, septic arthritis, and osteomyelitis is 3 weeks, 4 weeks, and 6 weeks, respectively.^{7,8,35} The C-reactive protein level and other markers of infection (eg, erythrocyte sedimentation rate, white blood cell count) may decrease in response to treatment, but clinical observation remains the best measure of management of infection.^{7,35} Once the infection is controlled, delayed reconstructive efforts may be considered.^{35,36}

Functional Outcomes

The heterogeneity of types of bites, time from injury to presentation, and the presence of injured structures makes the prediction of functional outcomes challenging. Early assessment of bite injuries, irrigation and débridement, and modern antimicrobial therapy have significantly improved outcomes of bites to the hand from humans, dogs, and cats. Patients who present early and are treated may have few sequelae. Delayed presentation or inadequate initial management, however, may lead to persistent infection, advanced joint destruction, and osteomyelitis.³⁶ Untreated septic arthritis has a profound effect on functional outcome, particularly if there is evidence of joint space narrowing or bony changes.⁴⁶ Once osteomyelitis develops, definitive treatment may require amputation.³⁶ Other complications include erosion of the flexor tendon and volar plate, tendon rupture,

Figure 5



A through **F**, Clinical photographs and radiographic imaging of the hand in a 59-year-old man who presented with right hand pain and swelling for 6 days. He had a 2-month-old healed puncture wound over the third metacarpal caused by a bite from the family German shepherd. **A**, Moderate swelling is visible over the third metacarpal, with mild erythema around the healed puncture. **B**, PA radiograph of the right hand demonstrating lucency in the metacarpal neck and a periosteal reaction on the ulnar aspect of the metacarpal diaphysis. **C**, Three-dimensional CT scan reconstruction demonstrating an osteolytic metaphyseal lesion and a fistulous tract through the third metacarpal to the mid diaphysis. **D**, Intraoperative photograph of the hand demonstrating surgical drainage, which was followed by curettage and excision of bone for culture. Swabs were negative for organisms, but the tissue culture showed multiple anaerobic species, including *Fusobacterium*, *Bacteroides*, and *Prevotella* species. **E**, PA fluoroscopic image of the hand following the curettage and excision of the infected area back to healthy bleeding bone. **F**, PA fluoroscopic image of the hand after insertion of antibiotic-loaded cement spacers into the dead space. These spacers were later removed.

and the development of tendon adhesions.

Summary

Because of the unique anatomy of the hand and the bacteriology of human and mammalian oral flora, bite in-

juries can lead to severe infection and functional impairment. Antimicrobial treatment is indicated for all bites to the hand regardless whether they are acute or severe and has significantly reduced the morbidity and mortality associated with these injuries. Surgical débridement can effectively decrease the development

of infection in select cases, and primary surgical repair and closure may be considered in select patients. Early assessment of bite injuries, irrigation and débridement, and modern antimicrobial therapy have been successful in reducing the morbidity, duration of treatment, and costs associated with hand bite injuries.

References

Evidence-based Medicine: Levels of evidence are described in the table of contents. In this article, references 17, 19, and 44 are level I studies. References 3, 4, 6, 21, 23, 42, 43, and 45 are level II studies. References 2, 32, and 40 are level III studies. References 1, 5, 8, 11, 13, 14, 16, 20, 25, 36, 41, and 46 are level IV studies. References 9, 10, 18, 24, 28-31, 33-35, and 39 are level V expert opinion.

References printed in **bold type** are those published within the past 5 years.

1. Jandl M, Grünauer J, Platzer P, et al: The management of bite wounds in children: A retrospective analysis at a level I trauma centre. *Injury* 2012;43(12):2117-2121.
2. Bregman B, Slavinski S: Using emergency department data to conduct dog and animal bite surveillance in New York City, 2003-2006. *Public Health Rep* 2012;127(2): 195-201.
3. Gilchrist J, Sacks JJ, White D, Kresnow MJ: Dog bites: Still a problem? *Inj Prev* 2008;14 (5):296-301.
4. Weiss HB, Friedman DI, Coben JH: Incidence of dog bite injuries treated in emergency departments. *JAMA* 1998;279 (1):51-53.
5. Nygaard M, Dahlin LB: Dog bite injuries to the hand. *J Plast Surg Hand Surg* 2011;45 (2):96-101.
6. Medeiros I, Saconato H: Antibiotic prophylaxis for mammalian bites. *Cochrane Database Syst Rev* 2001;2: CD001738.
7. Kwo S, Agarwal JP, Meletiou S: Current treatment of cat bites to the hand and wrist. *J Hand Surg Am* 2011;36(1):152-153.
8. Benson LS, Edwards SL, Schiff AP, Williams CS, Visotsky JL: Dog and cat bites to the hand: Treatment and cost assessment. *J Hand Surg Am* 2006;31(3): 468-473.
9. American Veterinary Medical Association Task Force on Canine Aggression and Human-Canine Interactions: A community approach to dog bite prevention. *J Am Vet Med Assoc* 2001;218(11):1732-1749.
10. Centers for Disease Control and Prevention: *Home and recreational safety: Dog bites*. <http://www.cdc.gov/HomeandRecreationalSafety/Dog-Bites>. Accessed September 25, 2014.
11. Sacks JJ, Sinclair L, Gilchrist J, Golab GC, Lockwood R: Breeds of dogs involved in fatal human attacks in the United States between 1979 and 1998. *J Am Vet Med Assoc* 2000;217(6):836-840.
12. Endom EE: Initial management of animal and human bites, in Post TW, ed: *UpToDate*. <http://www.uptodate.com/contents/initial-management-of-animal-and-human-bites>. Accessed October 5, 2014.
13. Patzakis MJ, Wilkins J, Bassett RL: Surgical findings in clenched-fist injuries. *Clin Orthop Relat Res* 1987;220:237-240.
14. Freeman AJ, Senn DR, Arendt DM: Seven hundred seventy eight bite marks: Analysis by anatomic location, victim and biter demographics, type of crime, and legal disposition. *J Forensic Sci* 2005;50(6): 1436-1443.
15. Oehler RL, Velez AP, Mizrachi M, Lamarche J, Gompf S: Bite-related and septic syndromes caused by cats and dogs. *Lancet Infect Dis* 2009;9(7):439-447.
16. Smith PJ, Lister G: Inflammation, in Smith PJ, Lister G, eds: *The Hand: Diagnosis and Indications*, ed 4. New York, NY, Churchill Livingstone, 1993, p 320.
17. Lindner DL, Marretta SM, Pijanowski GJ, Johnson AL, Smith CW: Measurement of bite force in dogs: A pilot study. *J Vet Dent* 1995;12(2):49-52.
18. Dewhirst FE, Chen T, Izard J, et al: The human oral microbiome. *J Bacteriol* 2010; 192(19):5002-5017.
19. Merriam CV, Fernandez HT, Citron DM, Tyrrell KL, Warren YA, Goldstein EJ: Bacteriology of human bite wound infections. *Anaerobe* 2003;9(2):83-86.
20. Talan DA, Abrahamian FM, Moran GJ, Citron DM, Tan JO, Goldstein EJ; Emergency Medicine Human Bite Infection Study Group: Clinical presentation and bacteriologic analysis of infected human bites in patients presenting to emergency departments. *Clin Infect Dis* 2003;37(11): 1481-1489.
21. Abrahamian FM, Goldstein EJ: Microbiology of animal bite wound infections. *Clin Microbiol Rev* 2011;24(2): 231-246.
22. Smith DK, Grohskopf LA, Black RJ, et al; U.S. Department of Health and Human Services: Antiretroviral postexposure prophylaxis after sexual, injection-drug use, or other nonoccupational exposure to HIV in the United States: Recommendations from the U.S. Department of Health and Human Services. *MMWR Recomm Rep* 2005;54(RR-2): 1-20.
23. Lohiya GS, Tan-Figuerola L, Lohiya S, Lohiya S: Human bites: Bloodborne pathogen risk and postexposure follow-up algorithm. *J Natl Med Assoc* 2013;105(1): 92-95.
24. Talan DA, Citron DM, Abrahamian FM, Moran GJ, Goldstein EJ; Emergency Medicine Animal Bite Infection Study Group: Bacteriologic analysis of infected dog and cat bites. *N Engl J Med* 1999;340 (2):85-92.
25. Westling K, Farra A, Cars B, et al: Cat bite wound infections: A prospective clinical and microbiological study at three emergency wards in Stockholm, Sweden. *J Infect* 2006;53(6):403-407.
26. Coburn B, Toye B, Rawte P, Jamieson FB, Farrell DJ, Patel SN: Antimicrobial susceptibilities of clinical isolates of HACEK organisms. *Antimicrob Agents Chemother* 2013;57(4):1989-1991.
27. Elliott SP: Rat bite fever and *Streptobacillus moniliformis*. *Clin Microbiol Rev* 2007;20 (1):13-22.
28. Hilliard J: Monkey B Virus, in Arvin A, Campadelli-Fiume G, Mocarski E, et al, eds: *Human Herpesviruses: Biology, Therapy, and Immunoprophylaxis*. Cambridge, United Kingdom, Cambridge University Press, 2007.
29. WHO Publication: Rabies vaccines: WHO position paper. Recommendations. *Vaccine* 2010;28(44):7140-7142.
30. Centers for Disease Control and Prevention: *Rabies*. <http://www.cdc.gov/rabies> Accessed September 25, 2014.
31. Centers for Disease Control and Prevention: Updated recommendations for use of tetanus toxoid, reduced diphtheria toxoid and acellular pertussis (Tdap) vaccine from the Advisory Committee on Immunization Practices, 2010. *MMWR Morb Mortal Wkly Rep* 2011;60(1): 13-15.
32. Babovic N, Cayci C, Carlsen BT: Cat bite infections of the hand: Assessment of morbidity and predictors of severe infection. *J Hand Surg Am* 2014;39(2): 286-290.
33. Elson RA: Rupture of the central slip of the extensor hood of the finger: A test for early diagnosis. *J Bone Joint Surg Br* 1986;68(2): 229-231.
34. Kemp A, Maguire SA, Sibert J, Frost R, Adams C, Mann M: Can we identify abusive bites on children? *Arch Dis Child* 2006;91(11):951.
35. Honda H, McDonald JR: Current recommendations in the management of osteomyelitis of the hand and wrist. *J Hand Surg Am* 2009;34(6):1135-1136.
36. Reilly KE, Linz JC, Stern PJ, Giza E, Wyrick JD: Osteomyelitis of the tubular bones of the hand. *J Hand Surg Am* 1997; 22(4):644-649.
37. Baddour LM: Soft tissue infections due to human bites, in Post TW, ed: *UpToDate*.

- http://www.uptodate.com/contents/soft-tissue-infections-due-to-human-bites?source=search_result&search=Soft+tissue+infections+due+to+human+bites&selectedTitle=1~150. Accessed September 25, 2014.
38. Baddour LM: Soft tissue infections due to dog and cat bites, in Post TW, ed: *UpToDate*. http://www.uptodate.com/contents/soft-tissue-infections-due-to-dog-and-cat-bites?source=search_result&search=Soft+tissue+infections+due+to+dog+and+cat+bites&selectedTitle=1~150. Accessed September 25, 2014.
 39. Shoji K, Cavanaugh Z, Rodner CM: Acute fight bite. *J Hand Surg Am* 2013;38(8):1612-1614.
 40. Basadre JO, Parry SW: Indications for surgical débridement in 125 human bites to the hand. *Arch Surg* 1991;126(1):65-67.
 41. Briden AJ, Povlsen B: Primary repair of a flexor tendon after a human bite. *Scand J Plast Reconstr Surg Hand Surg* 2004;38(1):62-63.
 42. Rui-feng C, Li-song H, Ji-bo Z, Li-qiu W: Emergency treatment on facial laceration of dog bite wounds with immediate primary closure: A prospective randomized trial study. *BMC Emerg Med* 2013;13(suppl 1):S2.
 43. Maimaris C, Quinton DN: Dog-bite lacerations: A controlled trial of primary wound closure. *Arch Emerg Med* 1988;5(3):156-161.
 44. Paschos NK, Makris EA, Gantsos A, Georgoulis AD: Primary closure versus non-closure of dog bite wounds: A randomised controlled trial. *Injury* 2014;45(1):237-240.
 45. Chen E, Hornig S, Shepherd SM, Hollander JE: Primary closure of mammalian bites. *Acad Emerg Med* 2000;7(2):157-161.
 46. Chadaev AP, Jukhtin VI, Butkevich AT, Emkuzhev VM: Treatment of infected clenched-fist human bite wounds in the area of metacarpophalangeal joints. *J Hand Surg Am* 1996;21(2):299-303.